


DERMOSCOPY TWO STEP ALGORITHM



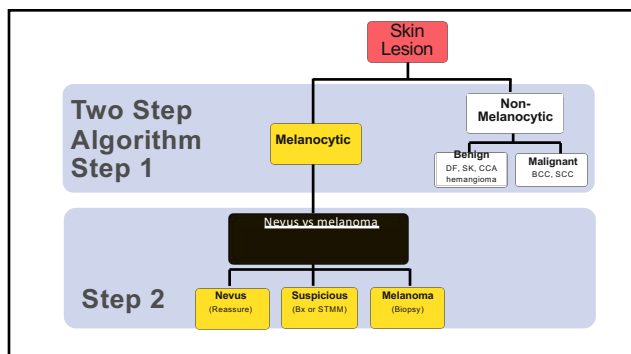
Two Step Algorithm Step 1



Richard P. Usatine, MD, FAAFP
 Professor, Dermatology and Cutaneous Surgery
 Professor, Family and Community Medicine
 Director, Underserved Family Medicine Dermatology Fellowship
 Founding Director, University Skin Clinic
 University of Texas Health, San Antonio

Disclosure Statement:





- Board, International Dermoscopy Society
- Associate Editor, Journal of Family Practice
- Family Medicine Editor, VisualDx
- Author, 10 medical books including lead author of:
 - The Color Atlas and Synopsis of Family Medicine*, 3rd Edition, McGraw-Hill, New York, 2019
 - The Color Atlas of Internal Medicine*, McGraw-Hill, New York, 2015
 - The Color Atlas of Pediatrics*, McGraw-Hill, New York, 2014
 - Cutaneous Cryosurgery*, 4th Edition, Taylor and Francis, London, 2014
 - Dermatologic and Cosmetic Procedures in Office Practice*, Elsevier, Inc., Philadelphia, 2012.
- Co-President, Usatine Media
 - medical app development company
- Photos in this presentation are from my clinical experience with some from Dr. Ash Marghoob

Learn an algorithm – place to start

- Ultimate goal is immediate pattern recognition
- Elephant method (Argenziano)



| | | |
|---|---|---|
| Non-melanocytic Pigmented tumors |  |  |
| Melanocytic tumors One pigmented and the other not pigmented |  |  |
| | Melanoma | Amelanotic melanoma |

Two-step diagnostic procedure

```

  graph TD
    A[Skin Lesion] --> B[Melanocytic]
    A --> C[Non-Melanocytic]
    B --> D[Is the lesion a melanocytic tumor?]
  
```

Step 1

Is the lesion a melanocytic tumor?

Two-step diagnostic procedure

Step 1

Melanocytic

Non-Melanocytic

Melanocytic tumors have:

1. Network (with two exceptions), aggregated globules, streaks, homogeneous blue pigment
- In addition (cover this in more detail later):
2. On volar skin (palms & soles) – parallel pattern
3. On face - Pseudo-network pattern

Melanocytic
(any location)


1. Network
2. Aggregated or peripheral rim of globules
3. Streaks
4. Homogeneous blue pigment

1. Network

Pigment network

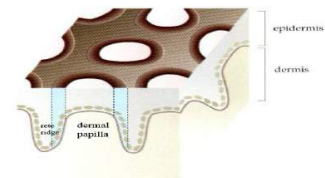
Negative network

Polygonal lines

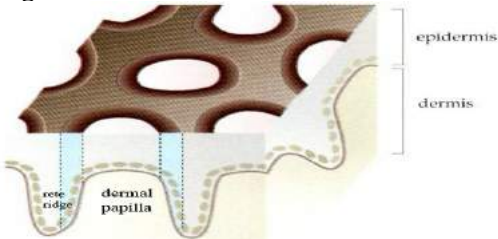


1a. pigment network (reticulation)

- Network lines correspond to the rete ridges.
- The “holes” correspond to tips of the dermal papillae

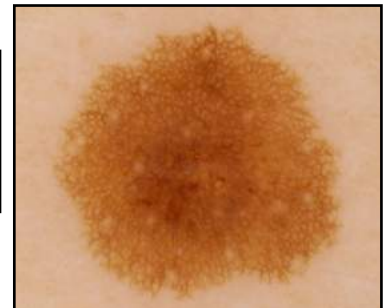
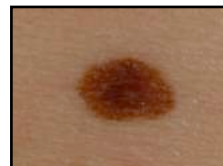
Pigment network

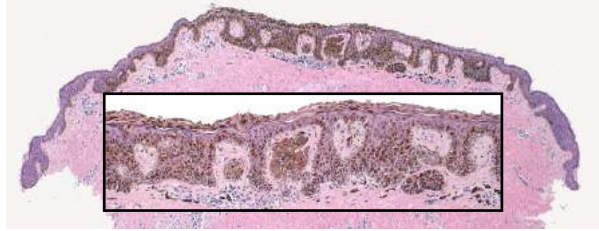


Nevus

Network



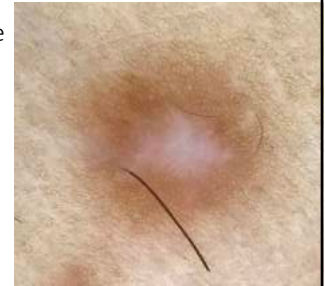Histopathologic specimen with elongated heavily pigmented rete ridge



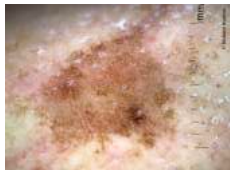
Exception 1:
Pattern trumps structure

DF- fine network
surrounding a central
scar like area

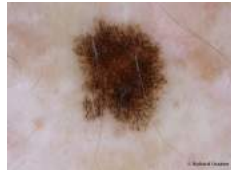Not melanocytic



Exception 2:
Pattern trumps structure



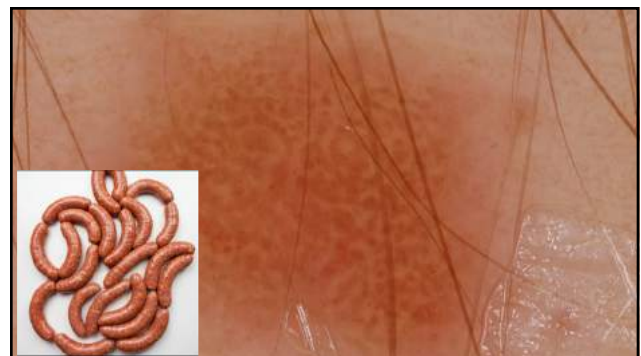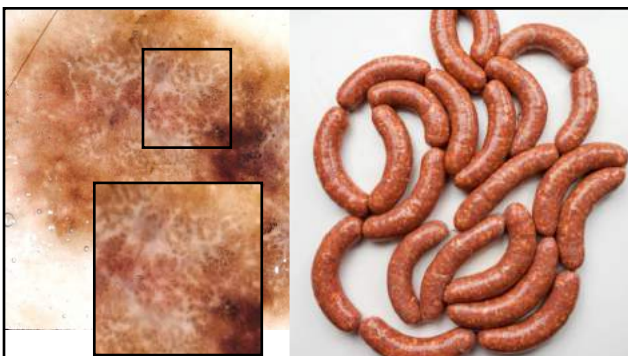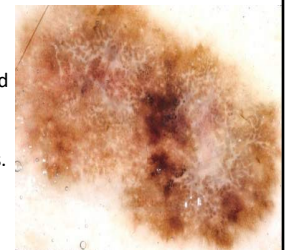
Solar lentigo: network
with moth eaten border

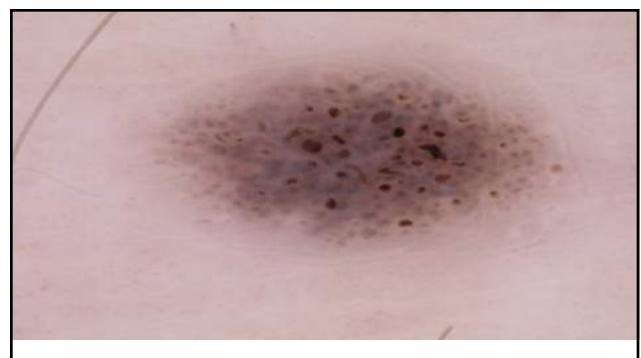
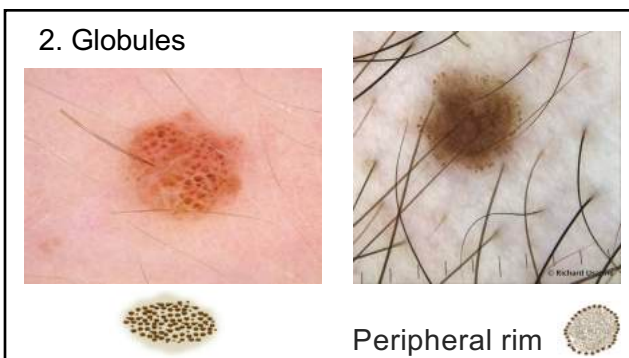
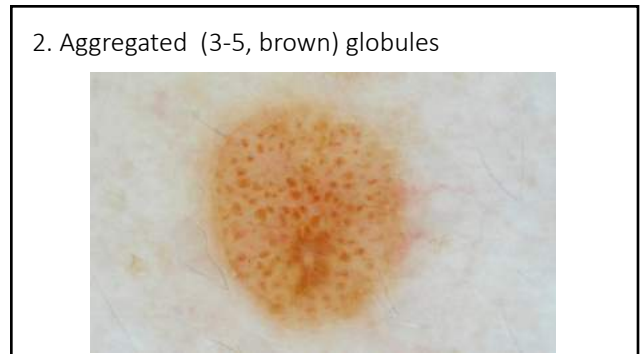
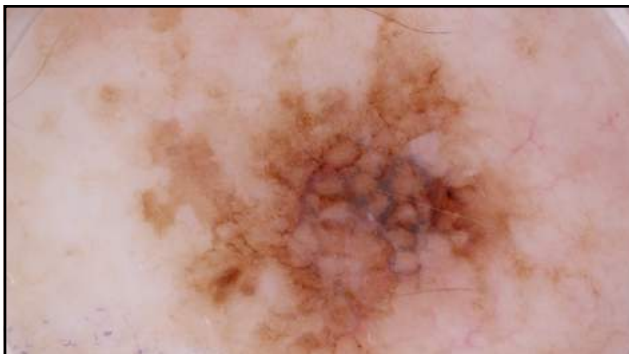
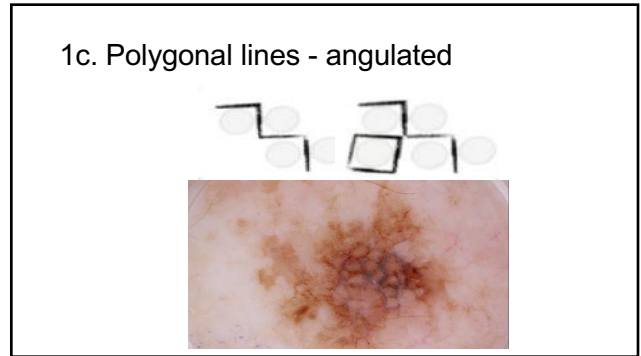
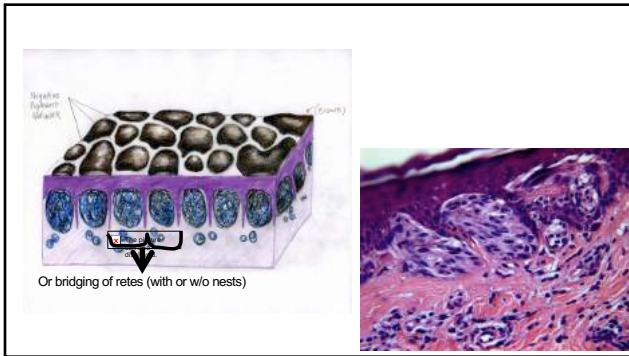


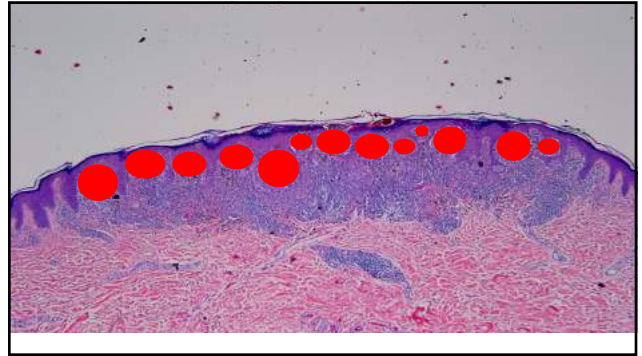
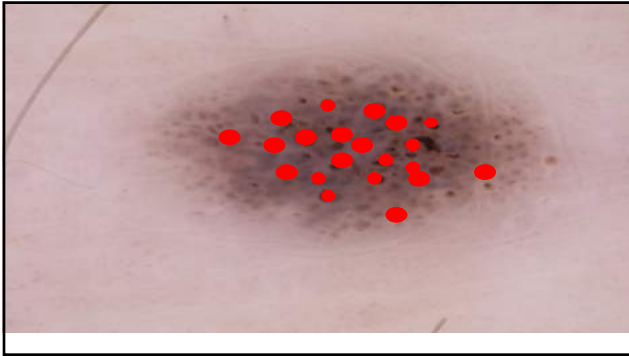
Ink spot lentigo:
uniform black network

1b. Negative network

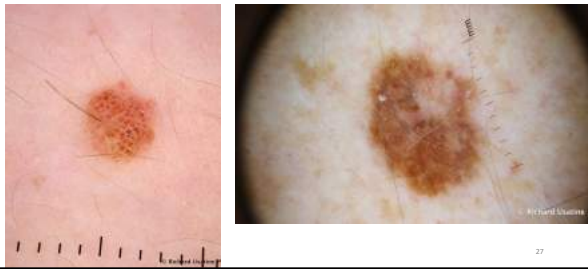
Serpiginous interconnecting
hypopigmented lines that surround
irregularly shaped pigmented
structures, which resemble
elongated and curvilinear globules.



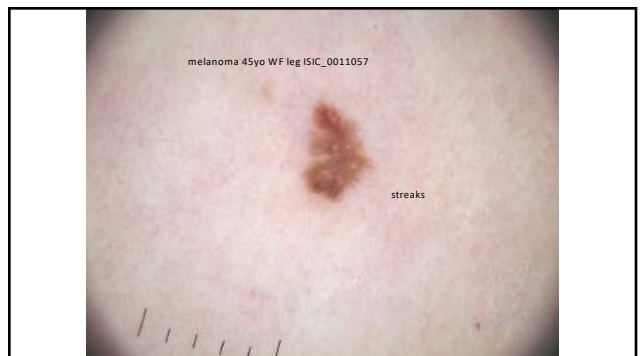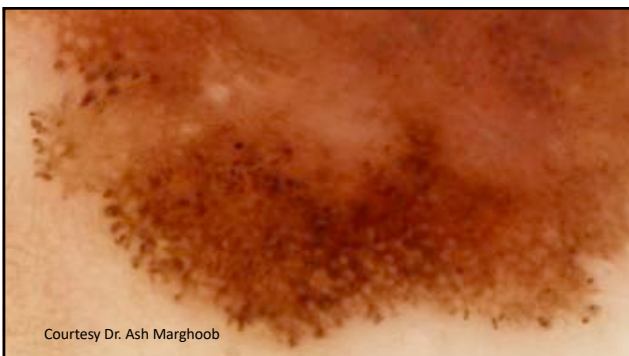

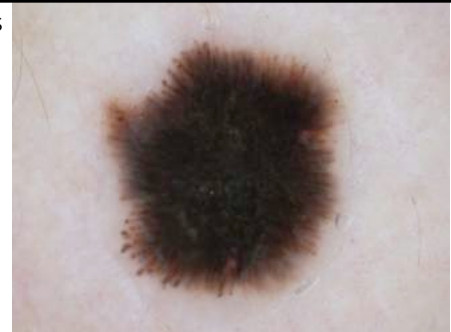
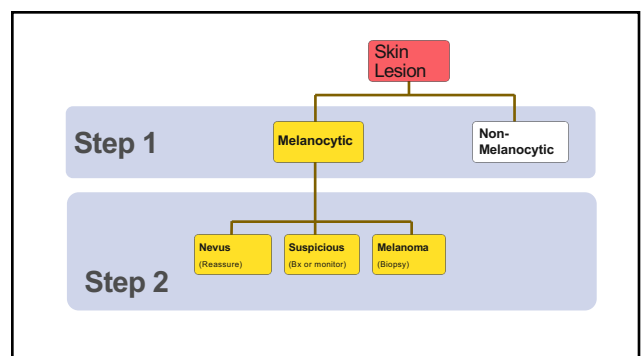
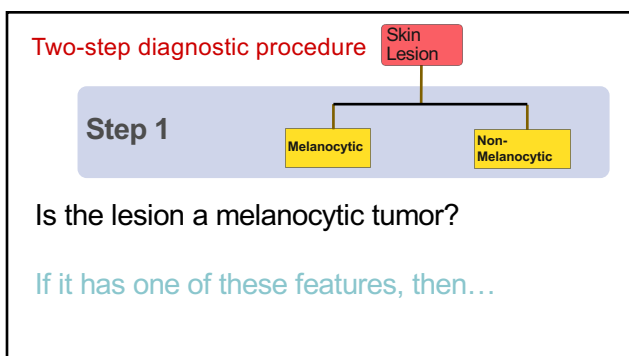
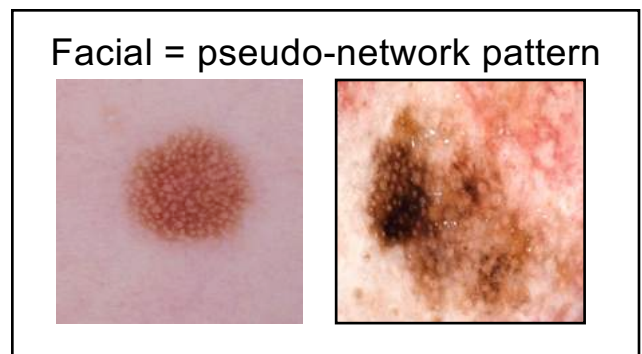
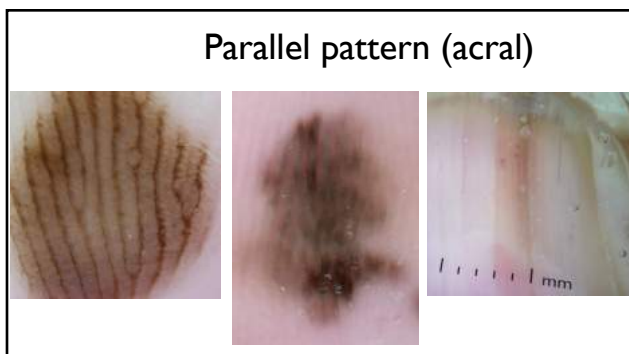
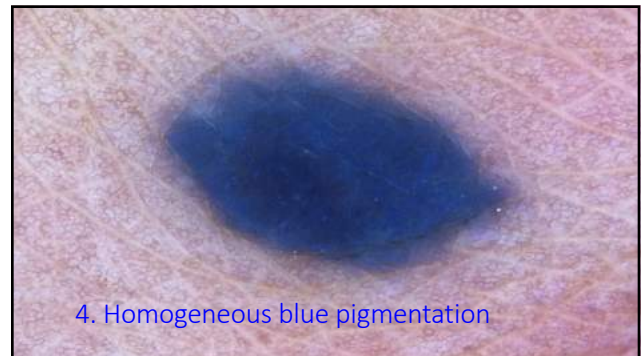


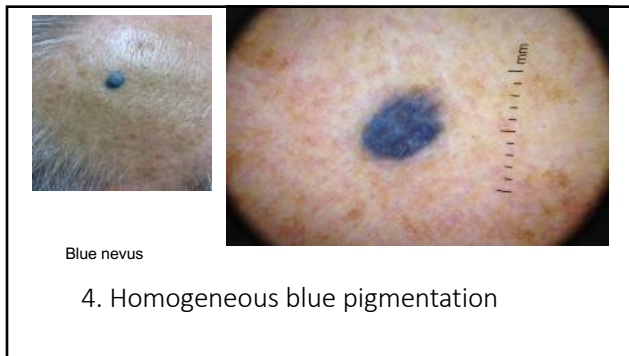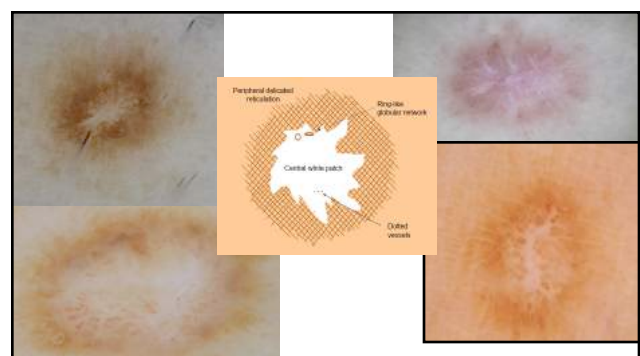
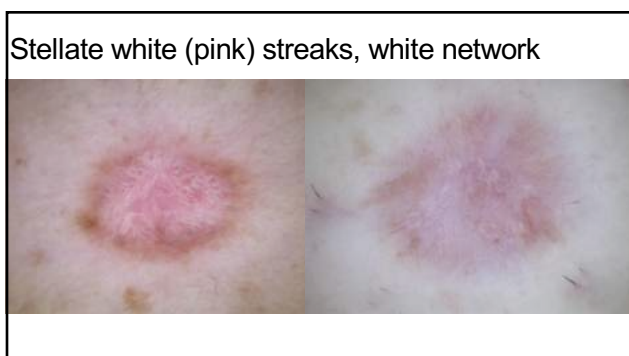
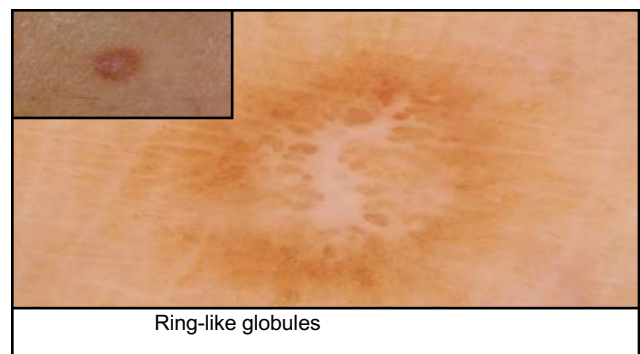
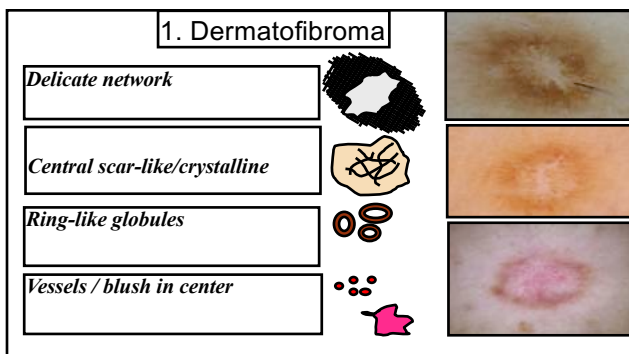
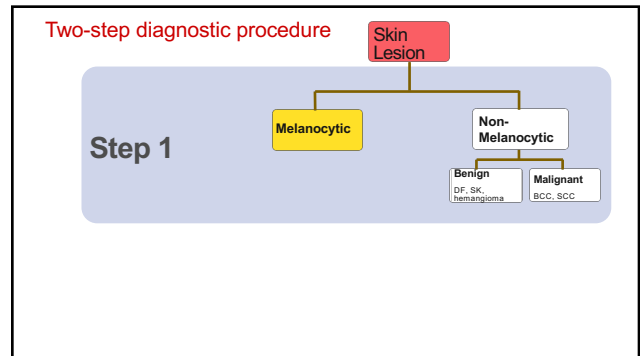
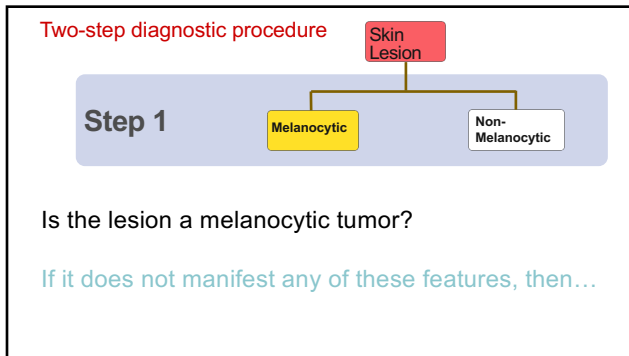
Globules vs negative network (elongated)









3. Streaks

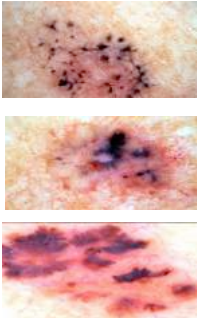







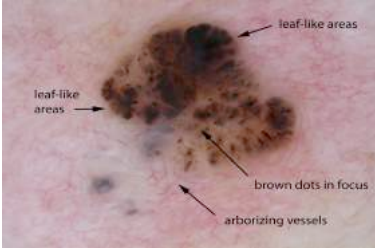
2. BCC

| Positive features (At least one present): | |
|---|---|
| Large grey-blue ovoid nests |  |
| Multiple grey-blue globules |  |
| Leaflike areas |  |
| Spoke wheel areas |  |
| Arborizing "tree-like" telangiectasia |  |
| Ulceration |  |



Leaf-like areas

- Brown to gray-blue discrete bulbous blobs
- "Leaf-like" pattern





Arborizing vessels - BCC

- In-focus, red, branching vessels
- Note white lines too

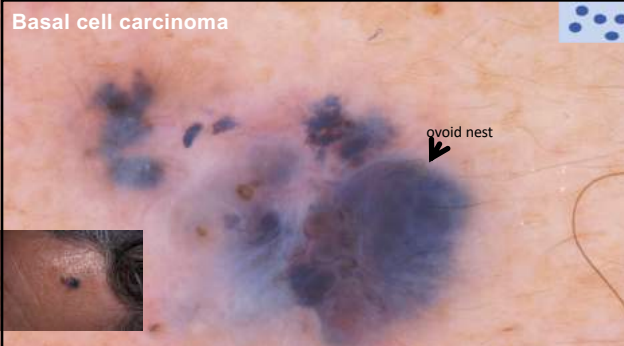



Blue-gray ovoid nests



© Richard Usatine, MD


Basal cell carcinoma



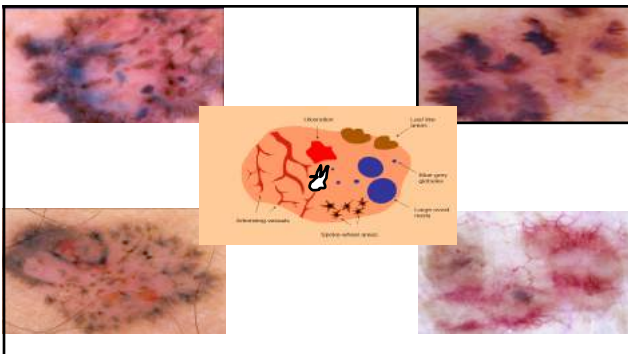
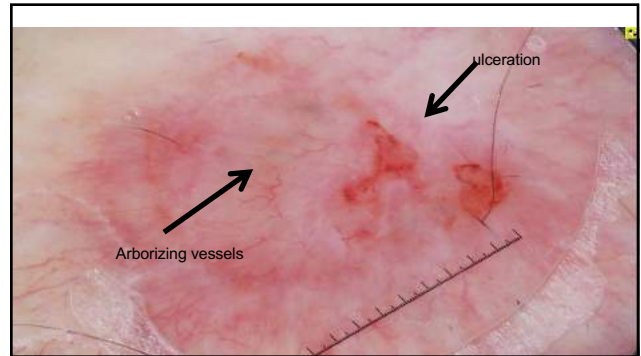
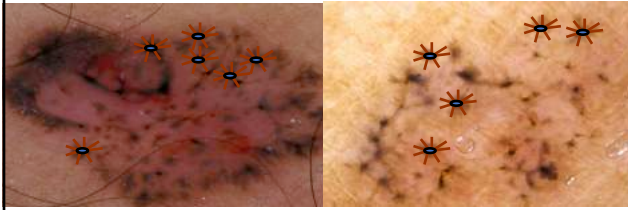
ovoid nest

Spoke-wheel-like structures

- Well circumscribed
- Brown to gray-blue-brown
- Radial projections
- Meeting at a darker brown central hub



Spoke-Wheel Structures



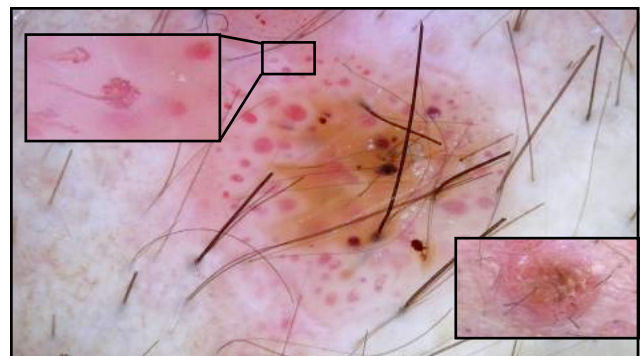
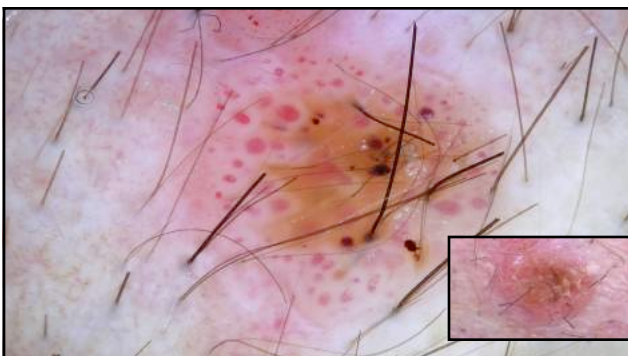
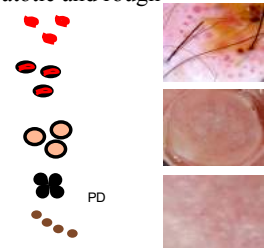
3. SCC

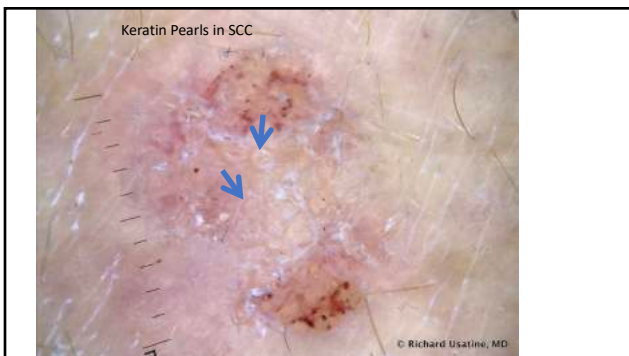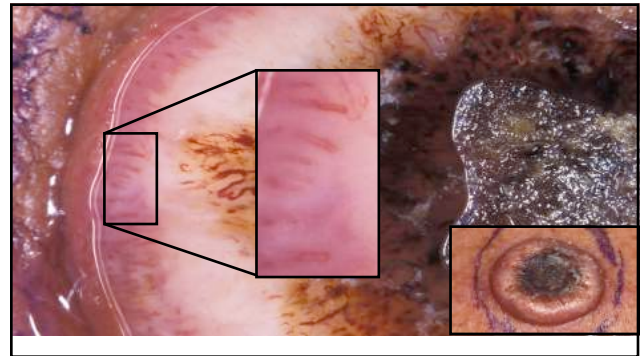
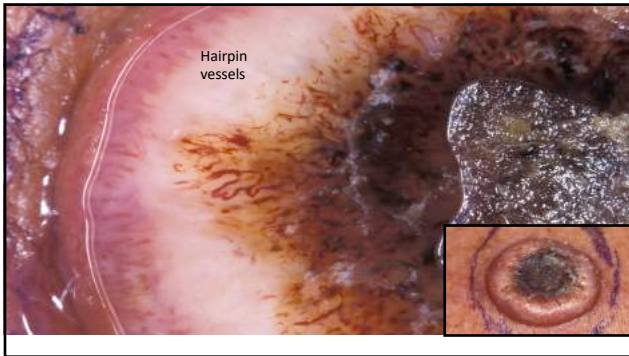
Focally scaly/keratotic and rough

Glomerular vessels
focally present at periphery

Hairpin vessels
usually with a white halo
Keratin pearls & white circles

Rosettes (strawberry pattern)
Brown dots/globules aligned in a linear fashion at the periphery



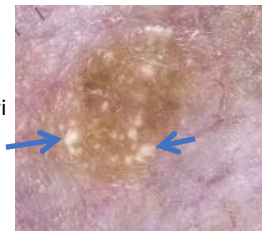


4. SK features

- Milia-like cyst
- Comedo-like opening
- Fissures & ridges
- Fat fingers
- Fingerprint-like
- Hairpin vessels
- Moth-eaten borders
- Well demarcated borders

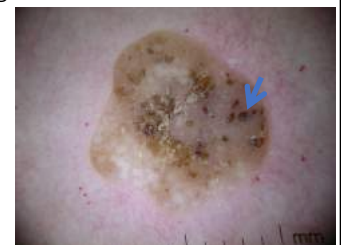Milia-like cysts

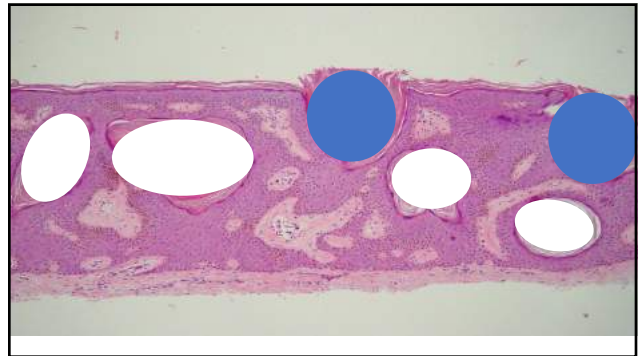
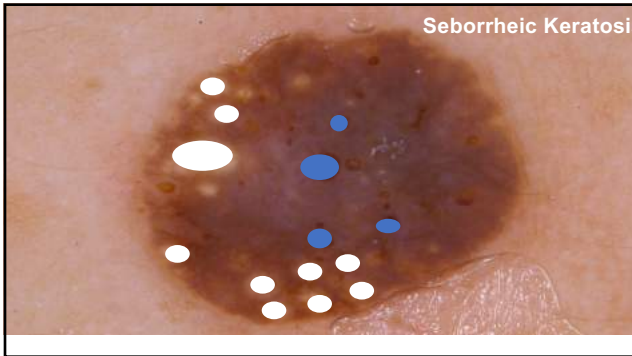
- Round whitish or yellowish structures
- Commonly seen in SKs
- Often seen in congenital nevi



Comedo-like openings

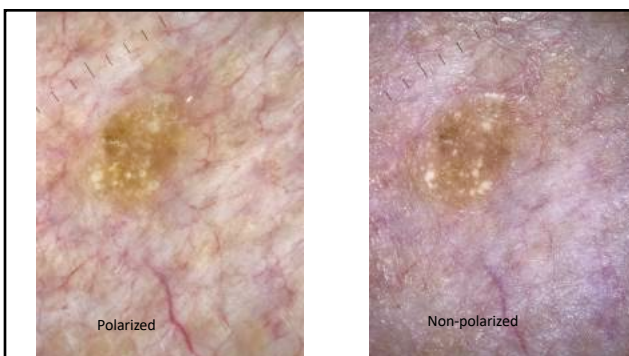
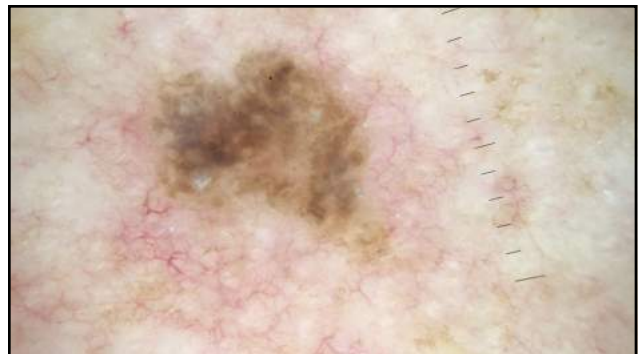
Keratin-filled invaginations of the epidermis





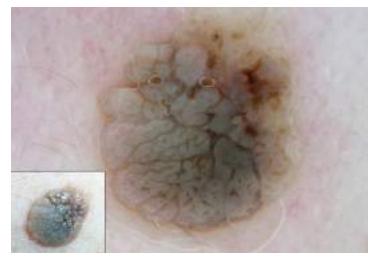
Milia cyst are more conspicuous under non-polarized light

- Milia cysts (superficial & small) are not as visible with polarized dermoscopy



SK - fissures & ridges

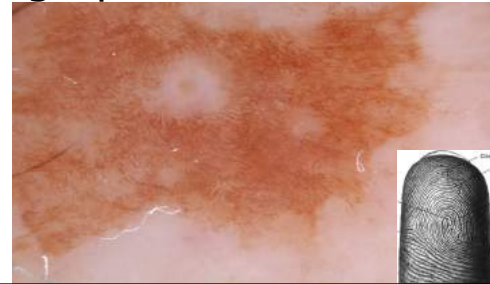
- Keratin patterns of epidermis - cerebriform



Fingerprint like network structures

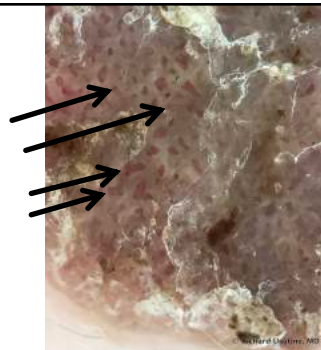
- Seen in solar lentigines and early seborrheic keratosis
- Tiny ridges running in parallel & resembling fingerprints

Fingerprint-like Structures



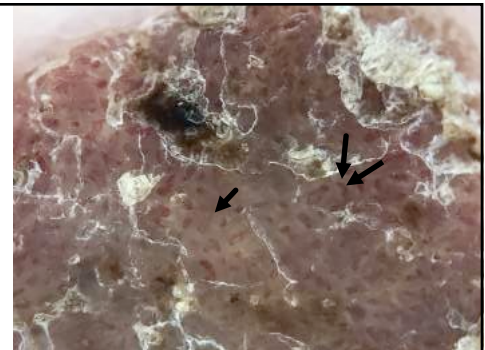
Hairpin vessels with a white halo in SK

- Looped vessels in papillary dermis
- White halo due to keratin

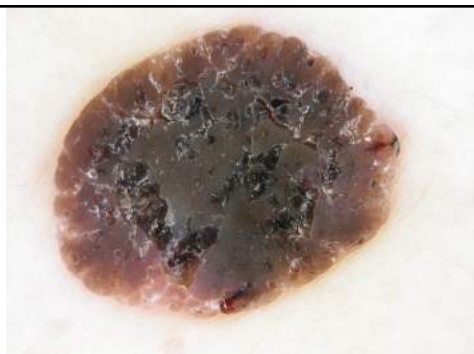


More hairpin vessels in an SK

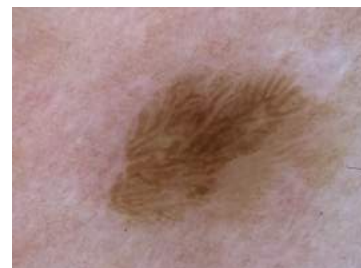They get twisted too (two arrows)

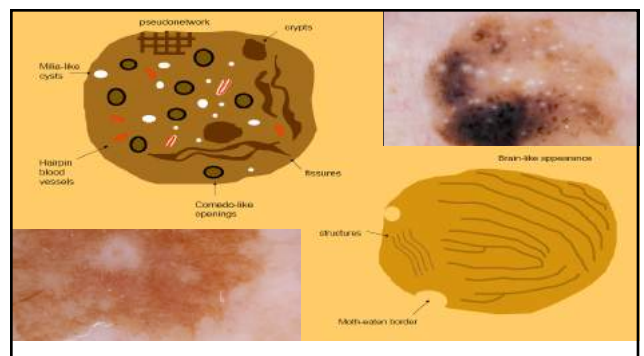
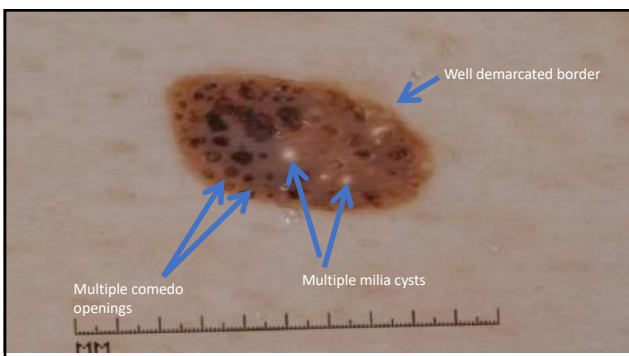

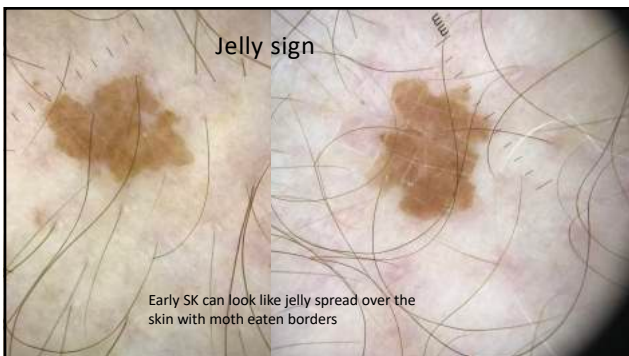
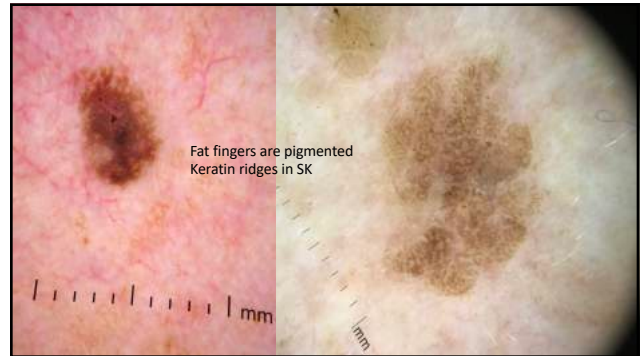
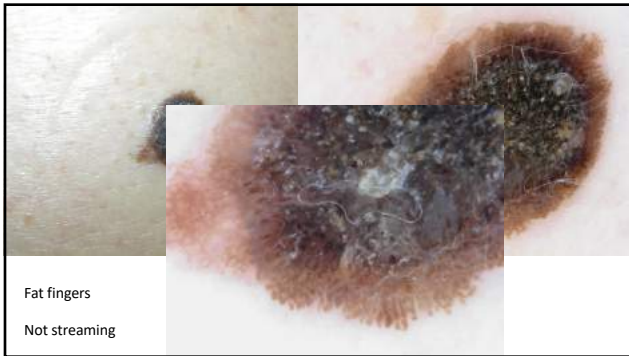


Well-demarcated border



Fat fingers are ridges and fissures looking like fingers

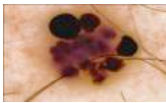
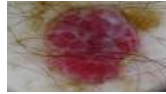
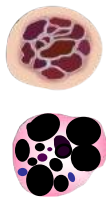



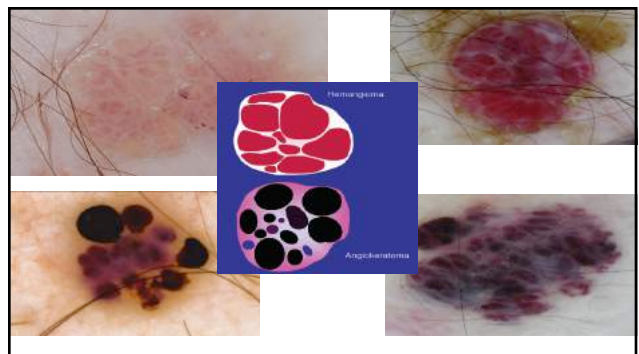
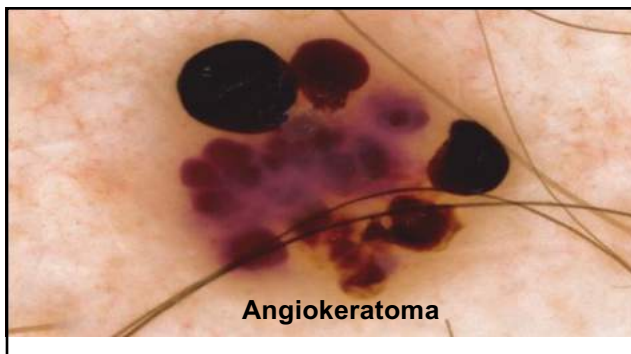
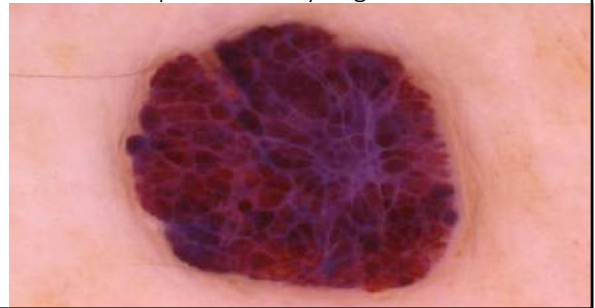
4. Vascular lesions

Lacunae separated by BWV septae

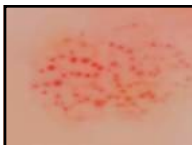red
maroon
blue
black
clear



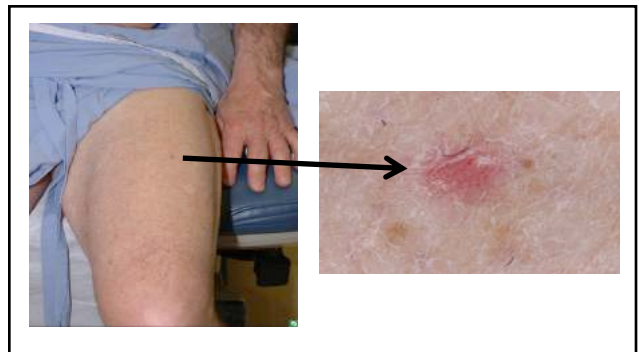Lacunae and septae in cherry angioma

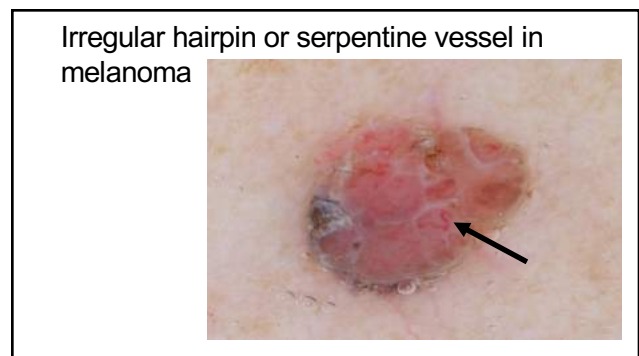
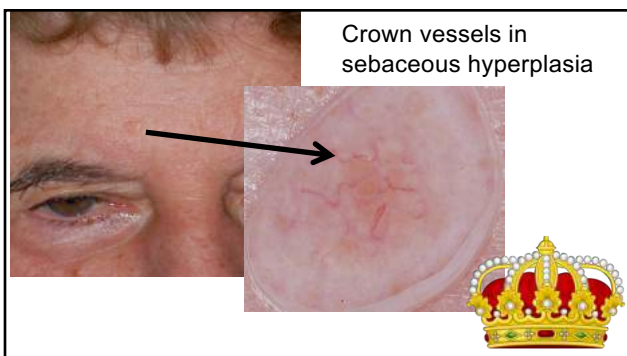
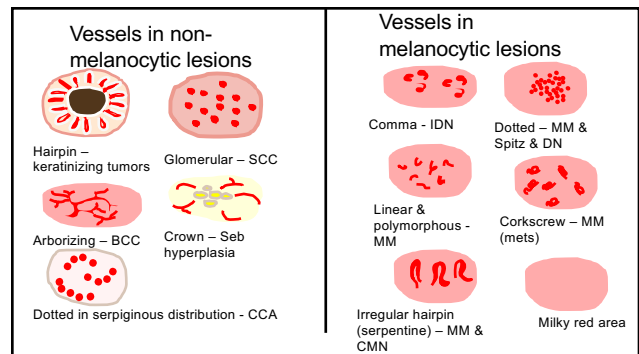
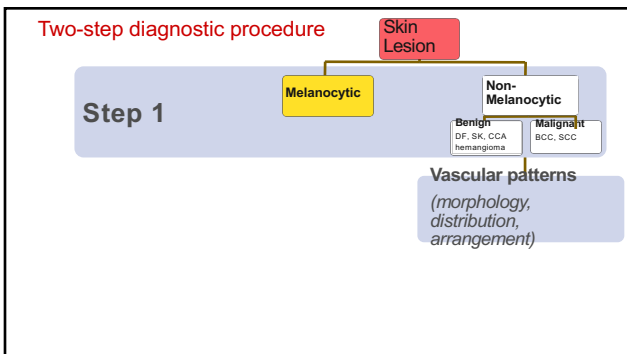
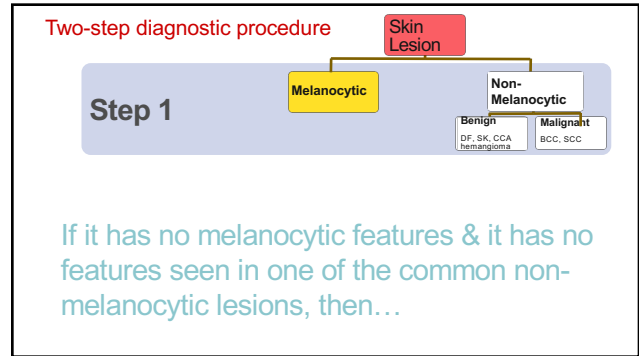
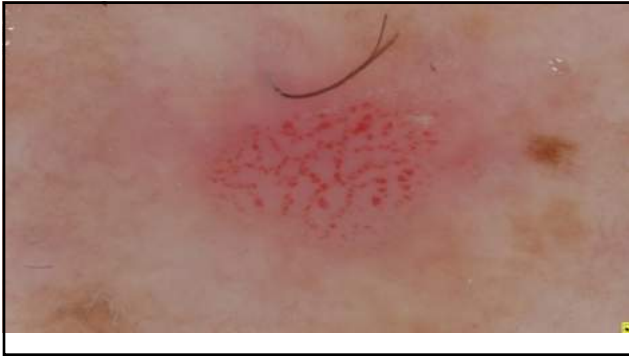

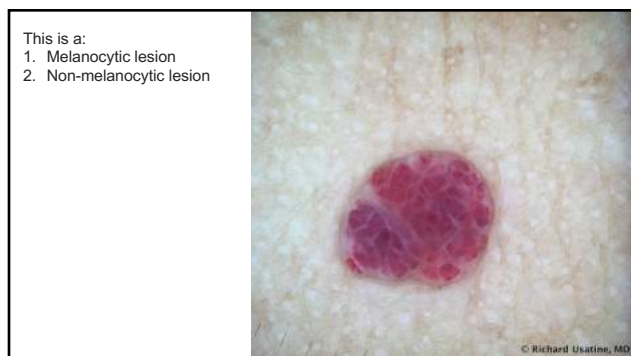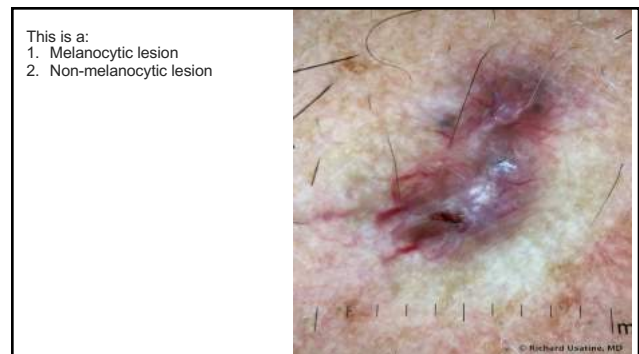
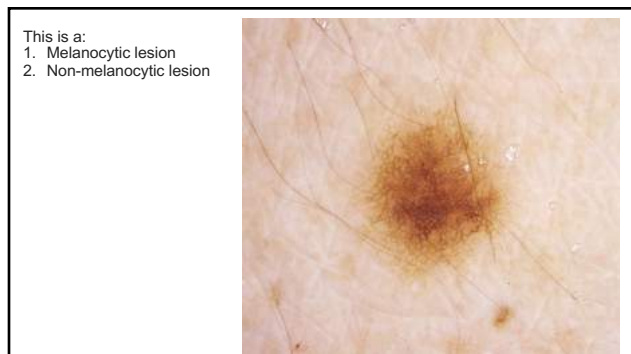
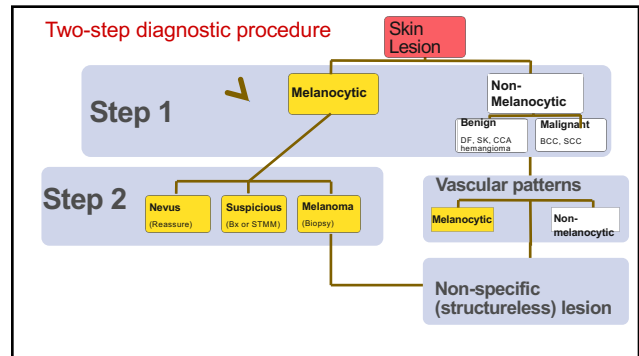
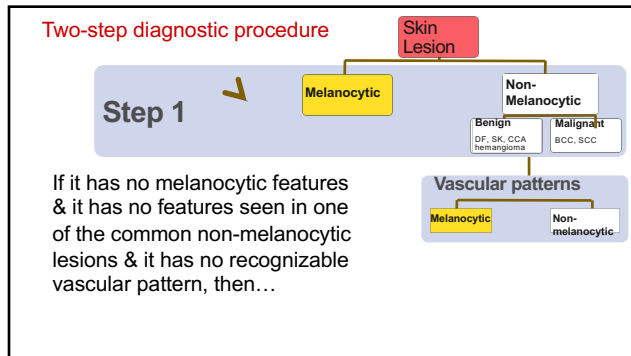
5. Clear cell acanthoma (benign tumor)

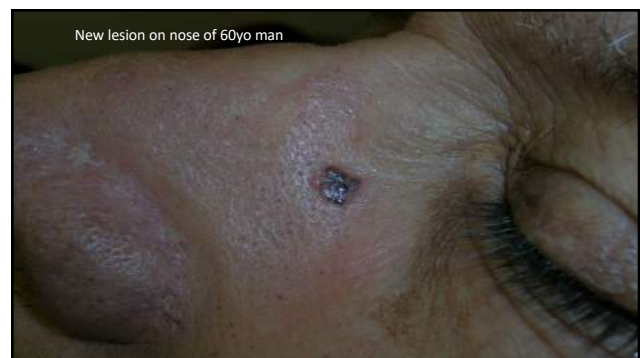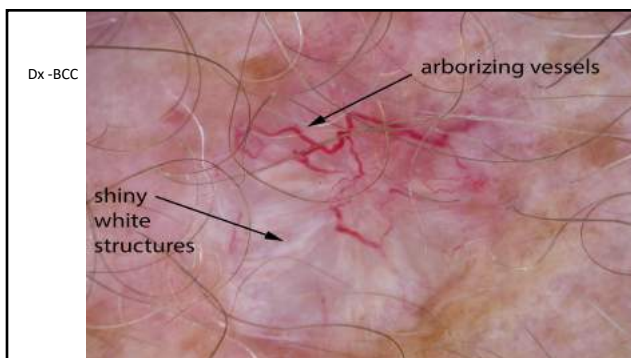
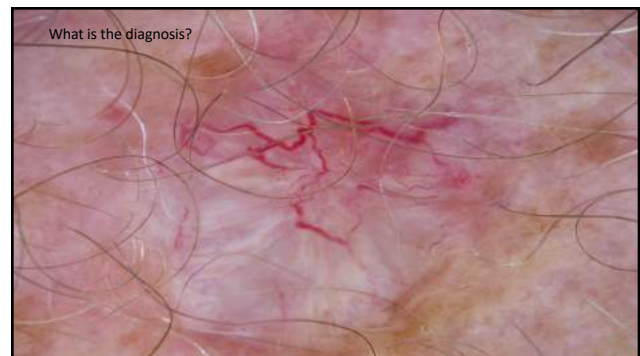
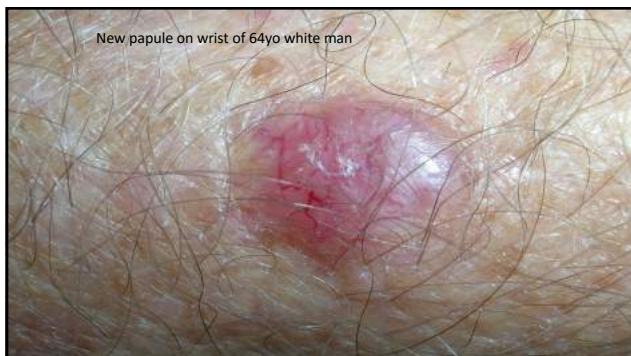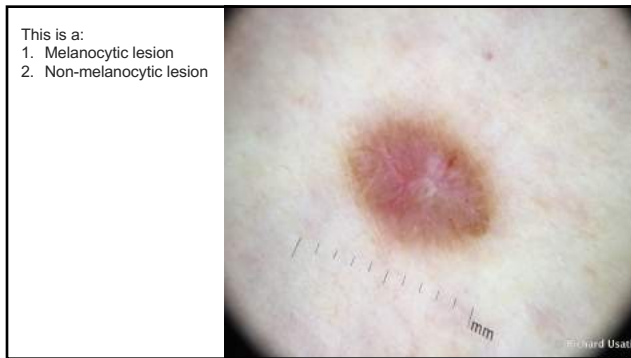


- Morphology/Distribution/Arrangement
 - Dotted or glomerular vessels distributed in a serpiginous pattern (string of pearls)
- Most commonly associated with
 - Clear cell acanthoma – PPV nearly 100%

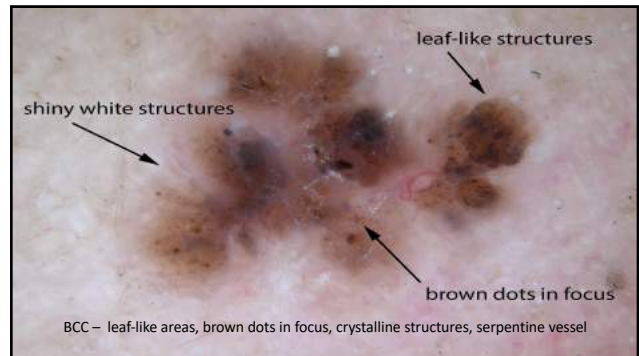
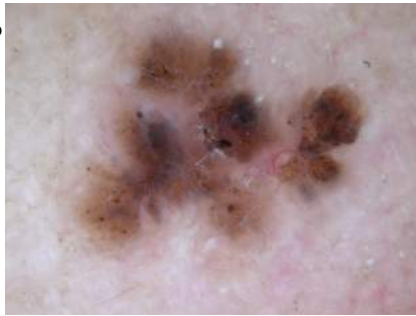




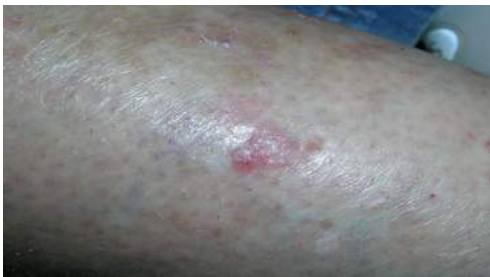



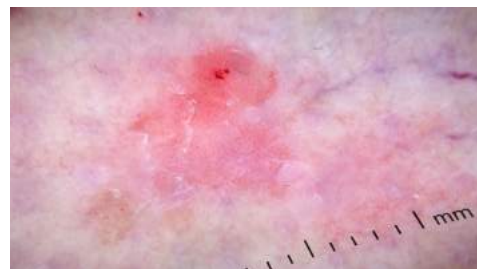
Diagnosis?



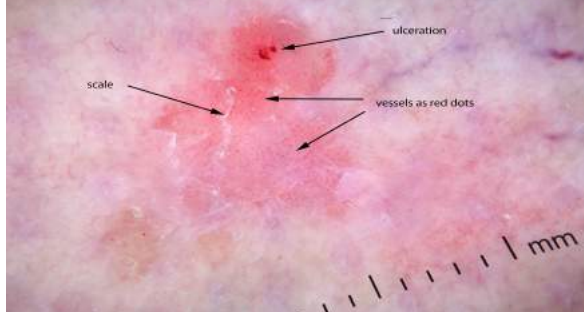
Area of scale and erosion on leg of 59 yo woman



What dermoscopic features do you see?
What is the diagnosis?



SCC in situ



26yo woman with lesion on arm



