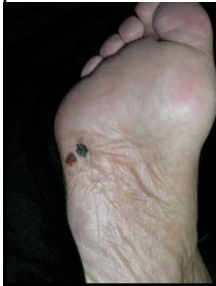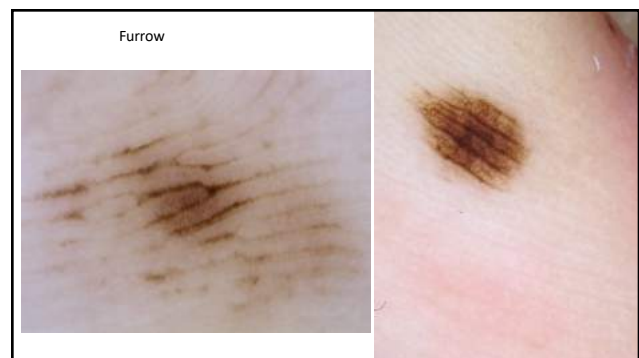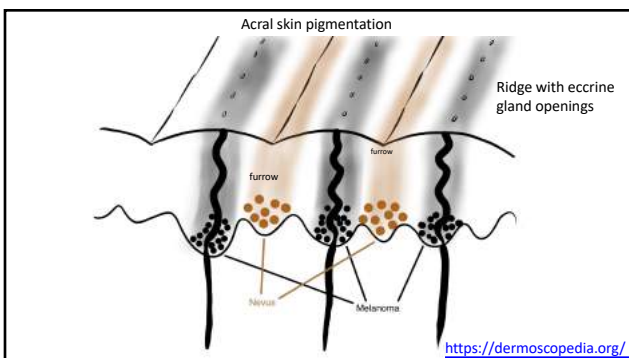
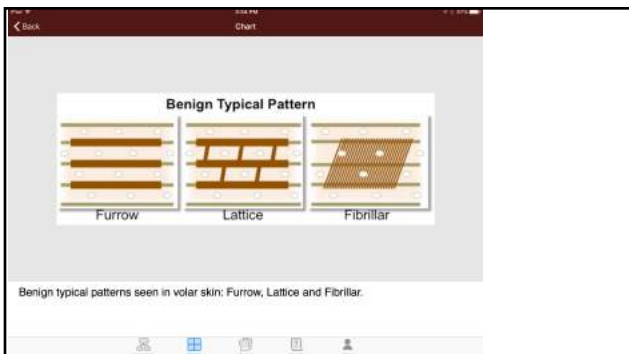

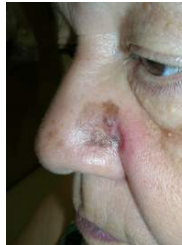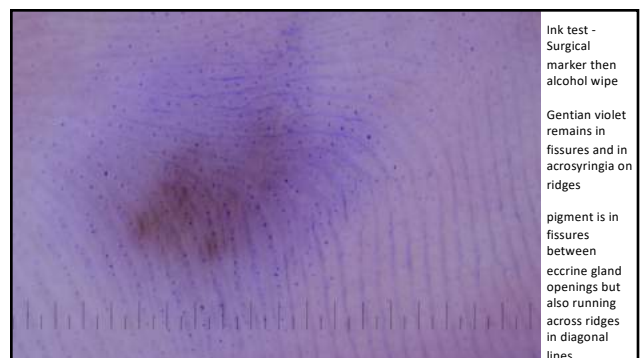
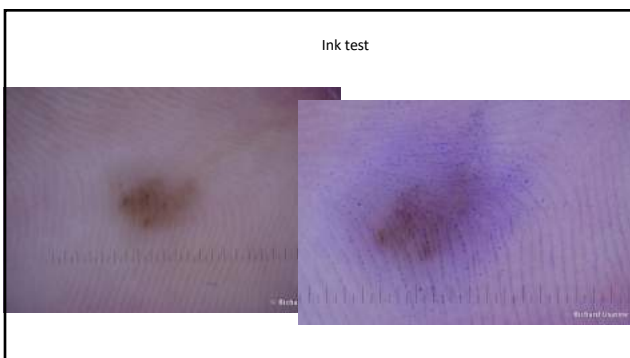


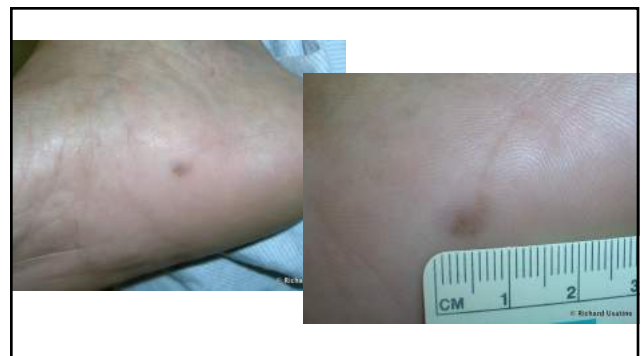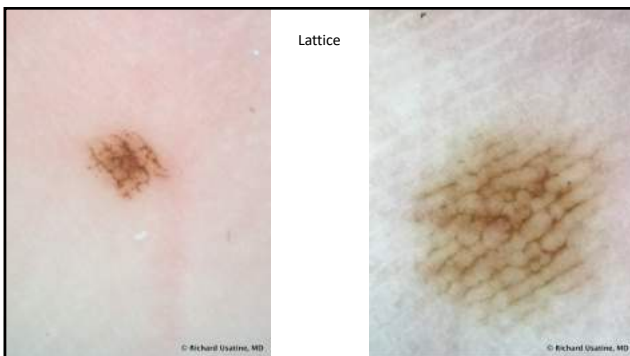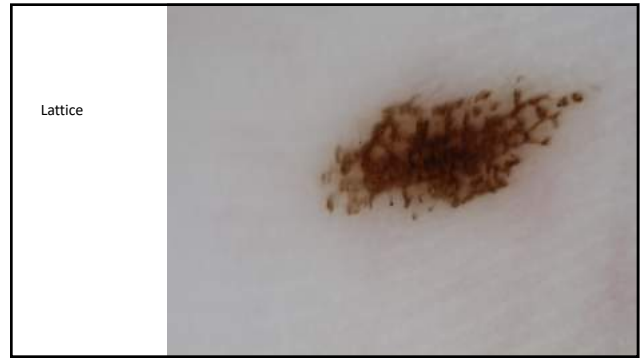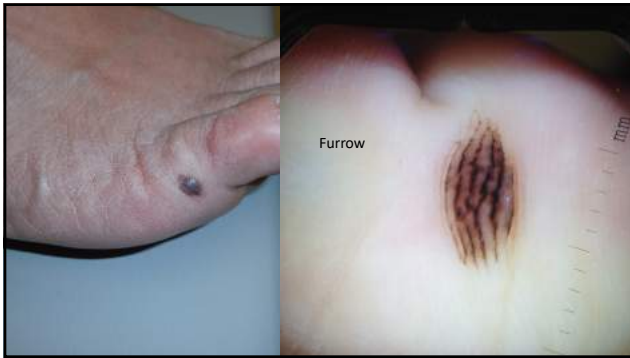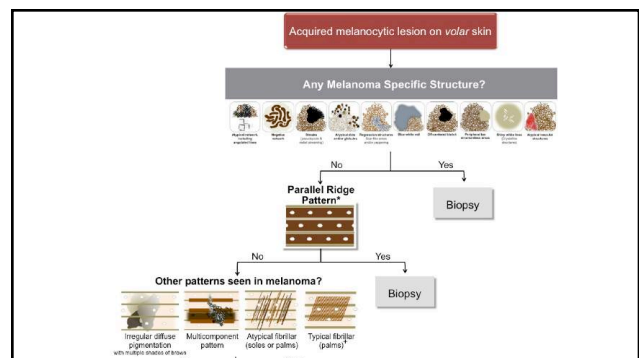
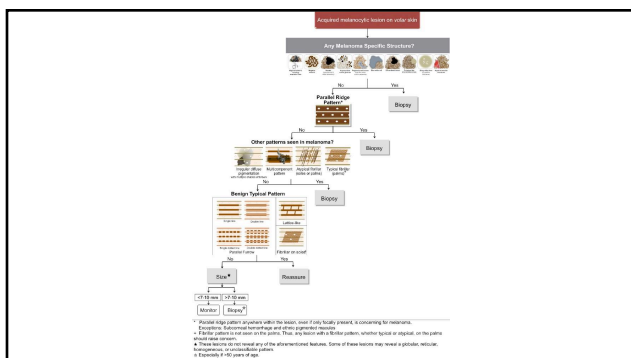
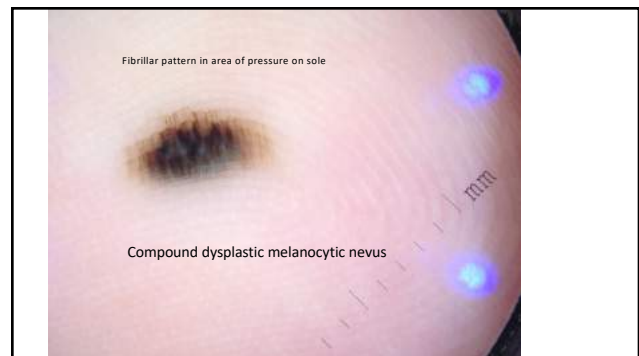
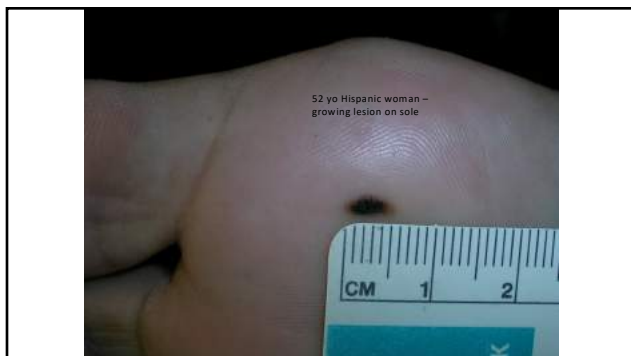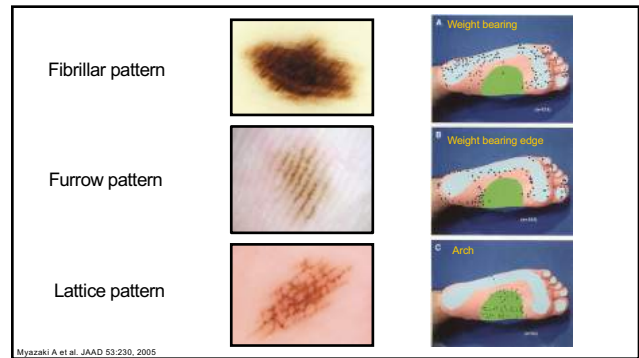
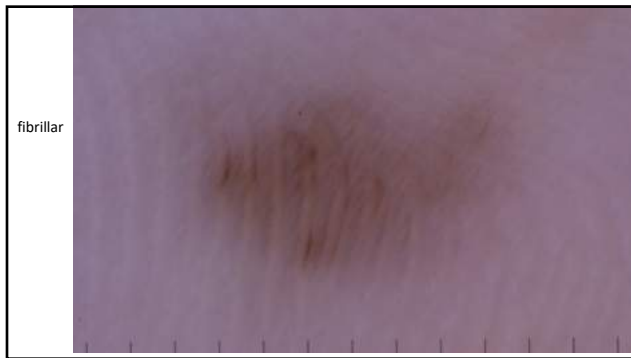Regional variations: Dermoscopy of Acral and Facial Skin

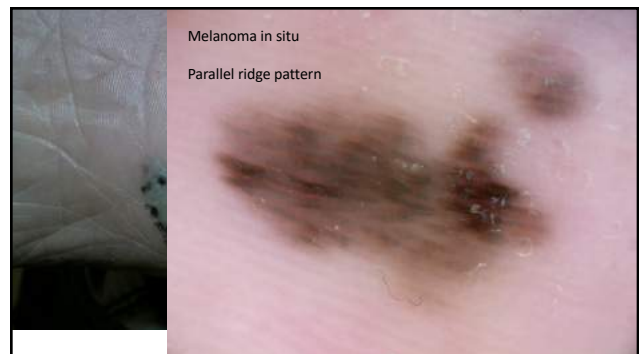
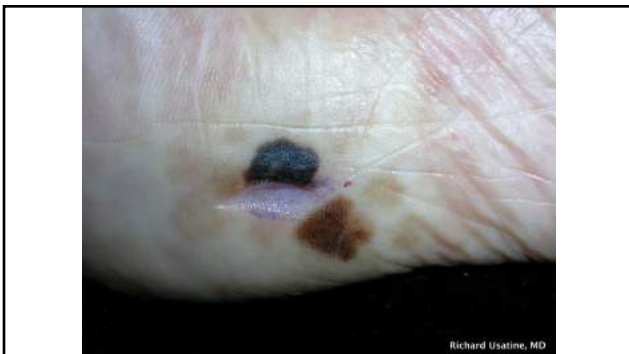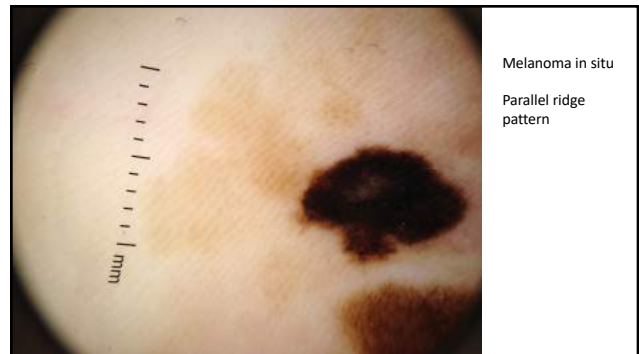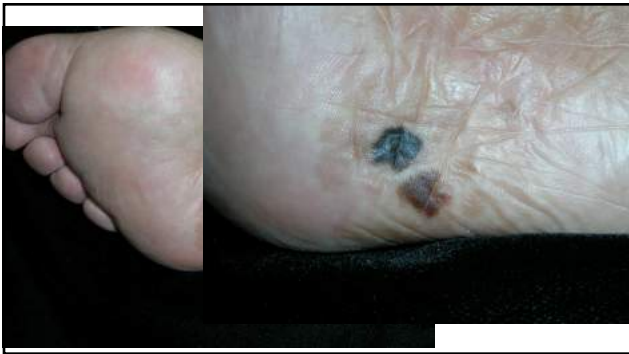
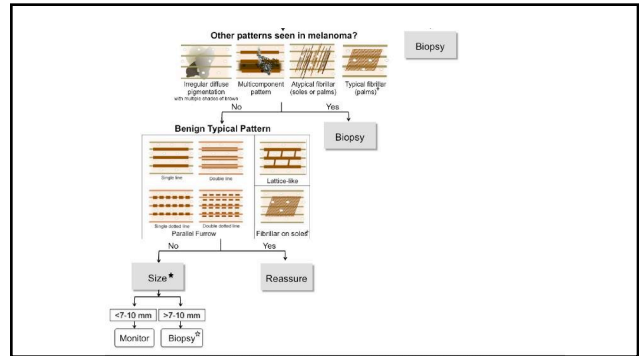
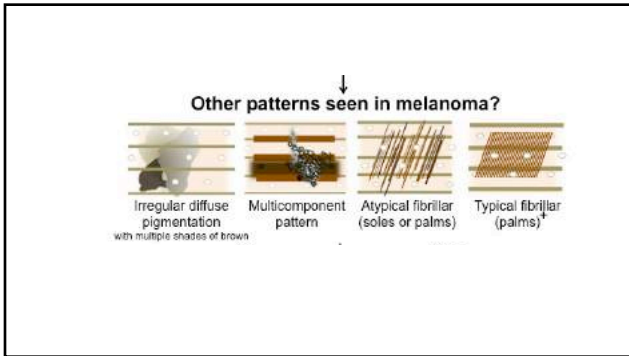


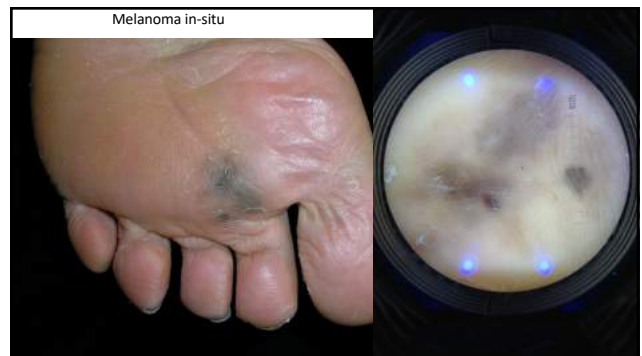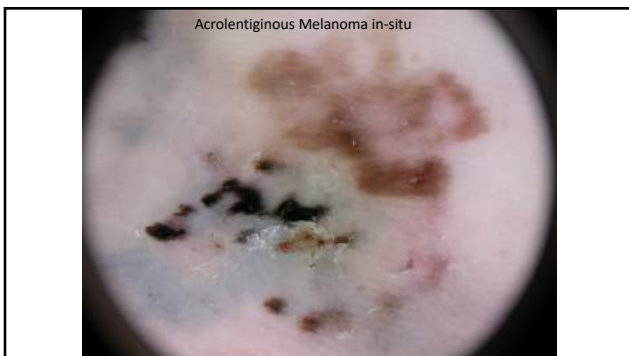
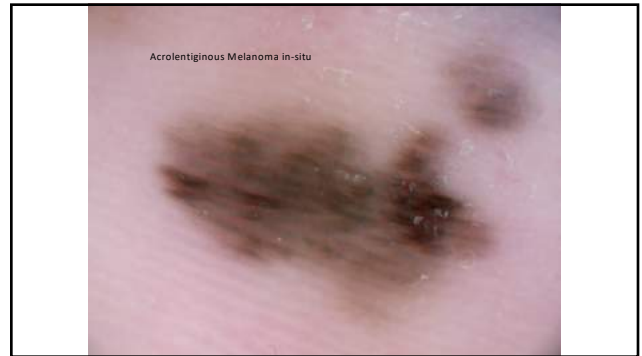
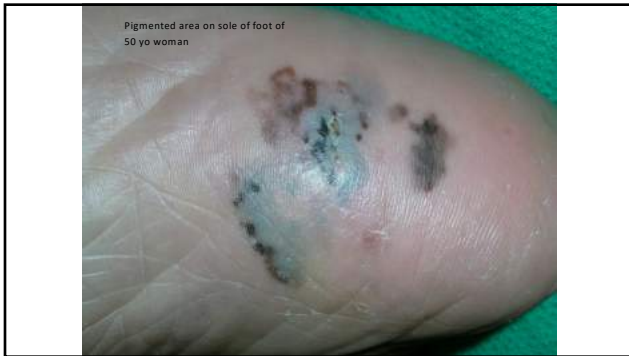Richard P. Usatine, MD, FAAP
Professor, Family and Community
Medicine
Professor, Dermatology and
Cutaneous Surgery
Founding Director, Skin Clinic
Program Director, Underserved
Dermatology Fellowship
University of Texas Health,
San Antonio











Exceptions on parallel ridge

- Ethnic pigmented macules = ethnic melanosis = Racial melanosis
- Hemorrhage

 A clinical photograph showing a small, dark, pigmented area on the sole of a foot, which is an exception to the parallel ridge pattern.